

Clinico-Hematological Features in Pure Red Cell Aplasia Patients Diagnosed at Diagnostic & Research Laboratory, Hyderabad

Faheem Ahmed Memon

*Diagnostic And Research Laboratory
LUMHS Jamshoro / Hyderabad*

Received: 17 Dec 2018

Revised: 30 January 2019

accepted for publication: 14 March 2019

Correspondence:

Dr. Faheem Ahmed Memon Diagnostic
And Research Laboratory
Liaquat University of Medical & Health
Sciences, Civil Hospital Hyderabad.
Email: drfamemon@hotmail.com

This article may be sighted as: Memon

**FA. Clinico-Hematological Features in
Pure Red Cell Aplasia Patients
Diagnosed at Diagnostic &
Research Laboratory, Hyderabad. LMRJ.
2019; 1(1): 2-4.**

Doi: 10.38106/LMRJ.2019.1.1-01.

Pure red-cell aplasia (PRCA) or erythroblastopenia is a rare type of anemia or disorder that can be either idiopathic or associated with certain autoimmune diseases and affect red blood cell (RBC) precursors^{1,2}. The disease is often present at birth, and it manifests in the first year of life in more than 90% of patients. It is a syndrome characterized by normochromic, normocytic anemia, reticulocytopenia (<1%), and an almost complete absence of erythroblasts (<0.5%) from the bone marrow³.

PRCA is categorized into congenital and acquired classes⁴. Studies elucidating the characteristics of PRCA in Pakistani population are very limited⁵. The current study was aimed to identify the clinical and hematological features in local PRCA patients.

This cross-sectional study was carried out at Diagnostic & Research Laboratory LUMHS Hyderabad from October 2014 to December 2016. Five patients from Diagnostic & Research Laboratory LUMHS Hyderabad referred for bone marrow biopsy were selected. After taking detailed history and physical examination, clinical and hematological findings were recorded on a pre-designed proforma. Bone marrow aspiration was done on all patients and trephine biopsies were taken where indicated⁶. Blood samples were taken and complete blood count (CBC) was performed on XN 1000 five parts fully automated haematology analyzer (Sysmex®, Japan). Peripheral blood films were stained with Leishman Stain and brilliant cresyl blue. These films were screened generally and the reticulocyte count was performed manually.

Patients with normochromic normocytic anemia, low reticulocyte count and isolated erythroblastopenia in the bone marrow were selected⁶. Whereas those with other types of anemia and patients with abnormal myelopoiesis and/or thrombopoiesis were excluded.

In the almost two years study duration, only two male and three female children, 9 months to 7 years in age, were diagnosed to have PRCA. Main clinical findings recorded among these patients were fever, weakness, weight loss and pallor. Abdominal distension was seen in one while hepatomegaly was seen in second patient. Four patients received their first blood transfusion in the first four months after birth, while one patient, received the first transfusion at one year age. Reticulocyte count was 0.6% and 1% in 2 patients while among the other three patients it was undetectable (Figure 1). Myeloid-to-erythroid (M/E) ratio in the bone marrow was found to range from 15:1 to 25:1. Leucopoiesis and megakaryopoiesis were found to be normal in all the cases.

A local study by Muneeza Natiq et al showed mean age of 4.12 years while in our study it was 3.8 years⁴. A study by Ball et al from London⁷ shows male to female ratio of 1.4:1 while in our study it was 3:2. In a study from India by Malhotra et al, pallor was found in all the patients; this is consistent with findings from the current study⁶. The mean hemoglobin concentration was 4.75 g/dl by El-Beshlawy et al from Egypt while in the present study it was 7.24 g/dl⁸. White blood cells count, platelets count and red cell indices were within normal limits in our study which was comparable to studies conducted by Muneeza Natiq et al and El-Beshlawy et al^{4,8}. The M/E ratio showed a much wider range (18:1 to 100:1) in the patients studied by Malhotra et al⁶.

The study was limited by the small sample size. We recommend more extensive studies conducted on larger number of patients from local population, in order to understand the clinico-hematological picture of the disease more accurately in local scenario. This study concluded that PRCA is a rare haematological disorder, commonly found in children. Fever, weakness and anemia are the common presenting features, whereas decreased RBC count, low hemoglobin concentration, low reticulocyte count and suppressed erythropoiesis on bone marrow examination are the main laboratory feature.

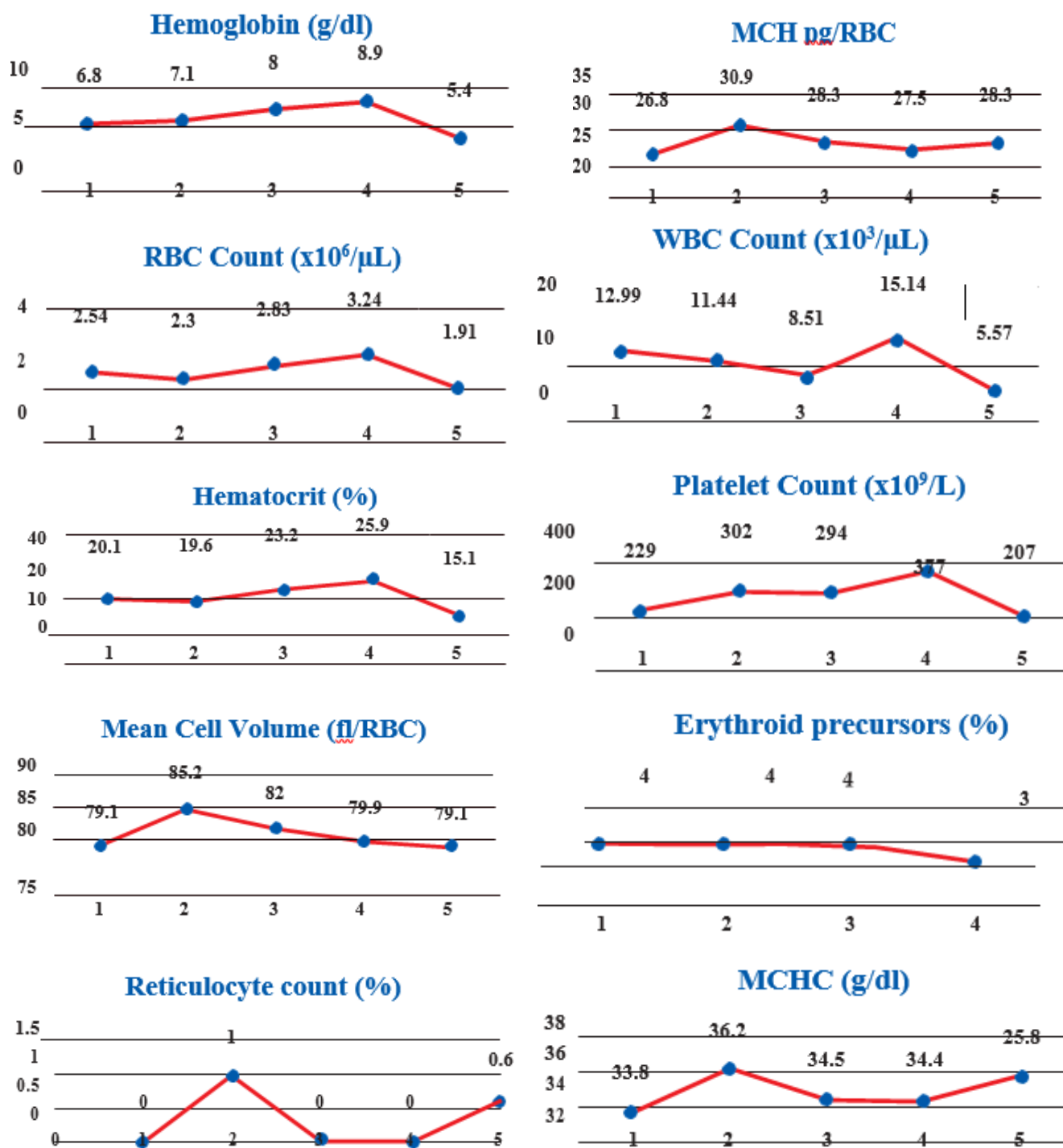


Figure 1. Key haematological parameters in the study patients. Arabic numerals on X-axis represent the five patients. Y-axis represent the test variable; the unit of measurement is provided in parenthesis alongside corresponding chart title. RBC, Red Blood Cell

*Erythrocyte precursors' percentage could not be elicited in patient number 5.

Acknowledgment: All lab staff of Diagnostic & research Lab LUMHS Hyderabad.

Conflict of Interest

I hereby declare that we do not have any conflict of interest related to publication of this article.

Grant Support/ Financial Disclosures

Diagnostic & Research Lab Hyderabad.

References

1. Fallahi S, Akbarian M, Dabiri S. Pure Red Cell Aplasia as a Presenting Feature in Systemic Lupus Erythematosus and Association with Thymoma, Hypothyroidism and Hypoparathyroidism: a Case Report and Literature Review. *Iran J Allergy Asthma Immunol* April 2014;13(2):138-143.
2. Yildirim R, Bilen Y, Keles M, Uyanik A, Gokbulut P, Aydinli B. Treatment of Pure Red-Cell Aplasia with Cyclosporine in a Renal Transplant Patient. *Experimental and clinical Transplantation* volume 11 number 1 February 2013.
3. Ozdena FO, Gunduzb K, Ozden B, Isci KD, Fisgin T. Oral and dental manifestations of Diamond-Blackfan Anemia: Case Reports. *Eur J Dent* 2011;5: 344-348.
4. Natiq M, Ahmad N, Rashid J. Frequency and Clinical-hematological features of Pure Red Cell Aplasia in children. *Pak J Med Health Sci* Apr - Jun 2010;4(2):82-8.
5. Shuaib A, Omer M, Naeemullah S, Latir Z. Pure Red Cell Aplasia: a single centre experience. *Pak J Pathol* Jan - Mar 2005;16(1):10-3.
6. Malhotra P, Muralikrishna GK, Varma N, Kumari S, Das R, Ahluwalia J, Jain S, Varma S. Spectrum of Pure Red Cell Aplasia in adult population of north-west India. *Hematology*. 2008 Apr;13(2):88-91.
7. Ball SE, McGuckin CP, Jenkins G, Gordon – Smith EC. Diamond Blackfan anemia in the United Kingdom – analysis of 80 cases from a 20 year birth cohort. *Br J Haematol* 1996; 94: 645–653.
8. El-Beshlawy A, Ibrahim IY, Rizk S, Eid K. Study of 22 Egyptians patients with Diamond Blackfan Anemia, Corticosteroid and cyclosporin therapy results. *Pediatrics* 2002; 110: 44.